

Scotland's Rural College

Liver gender dimorphism: insights from quantitative morphology

Marcos, R; Correia-Gomes, C; Miranda, H; Carneiro, F

Published in:
Histology and Histopathology

DOI:
[10.14670/HH-11-648](https://doi.org/10.14670/HH-11-648)

Print publication: 01/01/2015

Document Version
Peer reviewed version

[Link to publication](#)

Citation for published version (APA):

Marcos, R., Correia-Gomes, C., Miranda, H., & Carneiro, F. (2015). Liver gender dimorphism: insights from quantitative morphology. *Histology and Histopathology*, 30(12), 1431 - 1437. <https://doi.org/10.14670/HH-11-648>

General rights

Copyright and moral rights for the publications made accessible in the public portal are retained by the authors and/or other copyright owners and it is a condition of accessing publications that users recognise and abide by the legal requirements associated with these rights.

- Users may download and print one copy of any publication from the public portal for the purpose of private study or research.
- You may not further distribute the material or use it for any profit-making activity or commercial gain
- You may freely distribute the URL identifying the publication in the public portal ?

Take down policy

If you believe that this document breaches copyright please contact us providing details, and we will remove access to the work immediately and investigate your claim.

Liver gender dimorphism – insights from quantitative morphology

Ricardo Marcos^{1*}, Carla Correia-Gomes², Helena Miranda^{1,3,4}, Fatima Carneiro^{5,6,7}

1- Institute of Biomedical Sciences Abel Salazar, University of Porto, ICBAS-UPorto, Portugal

2- Epidemiology Research Unit, Future Farming Systems, Scotland's Rural College (SRUC), United Kingdom

3- Hepatic and Pancreatic Transplantation Unit, Santo António General Hospital, Centro Hospitalar do Porto, Portugal

4- Institute of Public Health of University of Porto (ISPUP), Portugal

5- Institute of Molecular Pathology and Immunology of the University of Porto (IPATIMUP), Portugal

6- Department of Pathology and Oncology, Faculty of Medicine of the University of Porto (FMUP), Portugal

7- Department of Pathology, Centro Hospitalar S. João, Porto, Portugal

Running title: Liver gender dimorphism

Keywords: Liver, gender, dimorphism, Hepatocytes, Kupffer cells

*Corresponding author: Ricardo Marcos

Institute of Biomedical Sciences Abel Salazar

Rua de Jorge Viterbo Ferreira, 228

4050-313 Porto, Portugal

E-mail: rmarcos@icbas.up.pt

Abstract

It was shown recently that many genes are differentially expressed in the liver of males and females, thus strengthening the concept of liver gender dimorphism. This dimorphism exists in many pathological scenarios, from regeneration to fibrosis, which has led to the development of gender hepatology. Nevertheless, it is still unknown if gender dimorphism occurs in the structure of the normal liver. In recent years, it has been shown that, compared with male, the female rat liver bears less fibrotic tissue, more Kupffer cells (per volume unit) and has higher hepatocellularity, including binucleated hepatocytes (per volume unit). Our hypothesis is that the human liver also hides a gender dimorphic pattern. Baseline differences in fibrotic tissue would contribute to explain severe liver fibrosis in men. As to the disparity of Kupffer cells, this would clarify the stronger response to post-surgery infections in women, and it could be equated when appraising the higher susceptibility to alcohol. Regarding differences in hepatocytes, they not only justify existing differences in some liver parameters (e.g., transaminases and bilirubin), but they could also account for the higher regenerative potential of the female liver. The structural dimorphism in the human liver would sustain the concept of gender hepatology and, eventually, should be considered in the context of liver transplantation.

Introduction

Recently, micro-array analysis revealed that more than half of genes were differentially expressed in male and female mice and rats (Yang et al., 2006; Kwekel et al., 2010) and in humans more than 1,200 genes have a gender biased expression (Zhang et al., 2011). This biological inequality is related with the so-called gender dimorphism, in which females have been favoured with increased resistance to premature ageing, nutrient deprivation, vascular and heart diseases, brain disorders, as well as hepatic neoplasms (Li et al., 2012). In the last decades, it has become increasingly evident that the liver is responsive to steroid sex hormones (both estrogens and androgens) which can modulate many functional features (e.g., Porter et al., 1987; Yasuda et al., 1999; Sereemaspun et al., 2005, Schleicher et al., 2015). Apart from differences in cytochrome P450, diverse contents of glucose-6-phosphatase and of glutamine synthetase have been reported (Teutsch, 1984; Sirma et al., 1996), and it has been shown that estrogens influence the levels of steroid-binding globulin and other circulating substances, like angiotensinogen, ceruloplasmin and transport proteins (Francavilla et al., 1986).

Studying liver gender dimorphism exceeds mere academic interest. In a clinical scenario, most surgeons feel better when performing a major intervention in a female liver than in a male one (Yokoyama et al., 2007). Moreover, under various types of stress, like ischemia and reperfusion injury, the organ presents a gender dimorphic pattern of response (Yokoyama et al., 2005). The mechanism underlying this is still debated: differences in the levels of circulating steroid sex hormones (estrogens and androgens), and of their receptors in the liver have been postulated to account for gender dimorphism (Sereemaspun et al., 2005; Yokoyama et al., 2005; 2007), but the different pattern of growth hormone secretion (Udy et al., 1997) and the more efficient generation of 3, 3', 5'-triiodo-L-thyronine in the liver of female rats may also play a role (Da Costa et al., 2001). It is noteworthy that the most updated techniques have been applied for studying gender dimorphism (Li et al., 2012). International research groups

devoted to this subject have been recently created (e.g., gender hepatology working group coordinated by E. Villa at University of Modena) and the subject is now starting to be reviewed (Guy and Peters, 2013; Durazzo et al., 2014).

By using stereological methods, hitherto unknown quantitative differences in the rat liver have been highlighted recently (Figure 1) (Marcos, 2013). In this study, male and female rat liver has been evaluated throughout ageing (2, 6, 12 and 18 months, n = 5 per group) and an emphasis has been given to a triumvirate involved in fibrosis and regenerative responses: hepatocytes (HEP), hepatic stellate cells (HSC) and Kupffer cells (KC). With the help of stereological tools (to estimate the total and relative number, as well as cell volume) it was concluded that, apart from differences in body and liver weight (Figure 1, Table 1), males and females differed in collagen content (greater in males) and in HEP and KC (Marcos, 2013; Marcos and Correia-Gomes, 2015). Regarding the former, differences existed in numerical density, mean cell volume and percentage of binuclear HEP (BnHEP) — *i.e.*, females had higher hepatocellularity, with smaller HEP, having more BnHEP. Similarly, females had higher numerical density of KC (Table 1) (Marcos and Correia-Gomes, 2014). Our hypothesis is that such gender dimorphism is also valid for the human liver.

It has been suggested that gender dimorphism is more pronounced in rodents (especially in rats, to a lesser extent in mice) than in humans (Mugford and Kedderis, 1998) and, obviously, rats cannot be viewed as “little humans” (and the high variability among humans may well be greater than gender differences). Nevertheless, dimorphic patterns of rats have been fairly mirrored in humans. For instance, differences in xenobiotic metabolism (Waxman and Holloway, 2009), liver fibrosis (Yasuda et al., 1999) or even in a basic parameter like liver weight have been described. Regarding the latter, Choukèr et al. (2004) evaluated 728 autopsies of men and women, aged 16 to 70 years, and concluded that the male liver is, on average, 16% heavier. This figure has been substantiated by recent studies using magnetic resonance imaging (Bian et

al., 2015). Likewise, in rats (Wistar strain) of age-related groups, males have a 49% heavier liver, on average (Marcos, 2013).

Differences in fibrous tissue

Except for autoimmune diseases, hepatic fibrosis is largely male dominant (Shimizu et al., 2007). Epidemiological studies have highlighted male gender as an independent predictor of fibrosis progression towards cirrhosis in hepatitis B and C-virus, as well as non-alcoholic steatohepatitis (NASH) (Di Martino et al., 2004; Zarski et al., 2006; Villa et al., 2012; Yang et al., 2014). In the rat, the same trend appears: throughout the years, different experimental studies have confirmed a stronger fibrosis in males, either using toxic compounds, like CCl₄ (Xu et al., 2002) or by inducing fibrosis by immune mediated mechanisms (Shimizu et al., 1999). Nevertheless, gender differences in the healthy liver are much more obscure, in rats as in humans. Even if the collagen content of the liver is much lower than in any other organ, significant gender differences in rats have been found: 2.5 *versus* 1.9% in males and females, respectively (Marcos and Correia-Gomes, 2015). Therefore, it is reasonable to hypothesize that such differences may also apply for humans, since studies using transient elastography (Fibroscan) in healthy patients have shown significant differences, pointing to greater extracellular matrix content in the male liver (Corpechot et al., 2006; Roulout et al., 2008; Colombo et al., 2011). In this vein, it may be argued that before the onset of fibrosis (NASH or HCV related), men would already have more fibrous tissue and an increased risk of severe liver fibrosis (Marcos and Correia-Gomes, 2015).

Differences in Kupffer cells

The liver harbors the largest population of mononuclear phagocytes in the body, accounting for 80% to 90% of the resident macrophages. These cells remove particulate and soluble material from portal blood, being fundamental in acute liver injuries and immunological responses. By producing several cytokines, KC establish a

cross-talk with HEP and HSC in hepatic regeneration and fibrogenesis (Tacke and Zimmermann, 2014).

It has long been known that proliferation of KC, as well as peaks of their phagocytic activity, are correlated with raised estrogen levels in the estrous cycle of rodents (Nicol and Veron-Roberts, 1965; Vickers and Lucier, 1996); for instance, ethinylestradiol (a major component of several combined oral contraceptive pills) induces a fivefold increase in KC proliferation *in vitro* (Vickers and Lucier, 1996). According to data of rats, estrogens also influence the normal liver, since the numerical density and number per gram of KC differ across genders, especially among younger animals (Marcos and Correia-Gomes, 2014). Despite being relatively unstudied in the liver, such dimorphism has been reported for other macrophages. Scotland et al. (2011) showed that female Wistar rats (as well as C57BL/6 mice) have 50% more macrophages in their pleural and peritoneal cavities. Moreover, these authors demonstrated that female peritoneal macrophages have more toll-like receptors, being more efficient in phagocytosis (these cells were associated with an increased population of resident T lymphocytes that prevented the excessive production of macrophage derived cytokines) (Scotland et al., 2011).

The functional consequences of such dimorphism in the liver could be immense. It could help explain the findings of trauma-haemorrhage models and the protection in female rats (Choudry et al., 2005), and it could be another piece in the puzzle to account for the lower severity and incidence of sepsis and post-surgery infections in women described by some authors (Schröder et al., 1998; Offner et al., 1999; Cohen et al., 2013). Besides numerical differences, hormones are also relevant: estrogens, for instance, exert anti-inflammatory and anti-oxidative actions, by inhibiting the production of pro-inflammatory tumour necrosis factor- α (TNF α), interleukin-1 β and -6 (Huang et al., 2008). Accordingly, the menopause is associated with spontaneous increases in the above mentioned cytokines in women (Pfeilschifter et al., 2002). Another functional consequence of KC dimorphism resides in alcohol susceptibility, which is greater in

females (rats as well as humans) (Colantoni et al., 2000; Eagon, 2010). Using an enteric feeding model, it was shown that young female rats had an increased pathology score, more marked infiltration by neutrophils and higher endotoxin levels, which ultimately was responsible for a stronger activation of KC, when compared with males (Thurman, 1998; Colantoni et al., 2000). Moreover, female KC had an increased production of TNF α and reactive oxygen species (Colantoni et al., 2000; Eagon, 2010). A classical study has already demonstrated a significantly strong correlation between endotoxin sensitivity and the number of KC in various species, including rats (McCuskey et al., 1984). Several factors have been proposed for explaining the gender dimorphic response to alcohol, namely, hormonal dysfunction, mitochondrial injury and oxidative stress, altered enzyme activities (e.g. of CYP2E1) and differences in gut permeability (Eagon, 2010; Durazzo et al., 2014). From our point of view, quantitative differences in KC may also have a part in this complex and intriguing equation.

Differences in Hepatocytes

To put it simply, we may say that for a plethora of harmful events that load the liver throughout life, the organ has only a handful of responses: 1) extracellular matrix deposition and fibrosis; 2) degeneration and intracellular accumulation; 3) necrosis and apoptosis; 4) inflammation; 5) regeneration. The liver is singular in this regard, as it is the only organ which, after being reduced to a third, is capable of an organized tissue growth to regain its original weight, with a fairly high precision (less than 10% variation) (Kam et al., 1987). After partial hepatectomy, quiescent HEP start to replicate, therefore restoring the functional liver tissue. A contribution for this is achieved by BnHEP, acting as an important cell reservoir that rapidly generates mononuclear HEP by amitotic cytokinesis (Gandillet et al., 2003).

Recently, it was shown that female rats have higher hepatocellularity with a larger proportion of BnHEP (Figure 1) (Marcos, 2013). We hypothesize that the same occurs in women, resulting in a higher regenerative potential. It is known that endogenous

estrogens increase after partial hepatectomy, eliciting a response by HEP (more than in KC): a rapid translocation of the estrogen receptor from the cytoplasm to the nuclei occurs and DNA synthesis is increased (Fisher et al., 1984; Vickers and Lucier, 1996). Experimental studies in rats have shown a higher regeneration in females (Tsukamoto and Kojo, 1990; Biondo-Simões et al., 2009; Kitagawa et al., 2009) and the scarce clinical data in humans points in the same direction (Imamura et al., 1999). After a hepatectomy of 50%, Shan et al. (2005) observed a significantly increased regeneration in women compared with men. In another study, the increase in the non-embolized liver lobe after portal vein embolization was 3.8% higher in women compared with men (Yokoyama et al., 2008). Notably, a short-term adjuvant therapy of estrogen has already been proposed for promoting liver regeneration after partial hepatectomy, in patients with poor liver function (Chiu et al., 2002).

Apart from differences in regeneration, the higher hepatocellularity of female rats corroborates the larger functional reserve for this gender. In fact, it is nowadays recommended to use different normal reference levels for aminotransferase activity in men and women (Ruhl and Everhart, 2002). Moreover, the remnant liver volume needed to avoid hepatic dysfunction and complications after right hepatectomy (in living donation) differs between genders (Facciuto et al., 2013). Differences in hepatocellularity could help explain the disparity in hepatic transport of organic anions such as sulfobromophthalein, indocyanine green — these are transported to a greater extent in female liver, in rats as well as in humans (Torres, 1996; Morris et al., 2003). Variable clearance of sulfobromophthalein exists with intact animals and perfused livers, but ceases when plasma membrane vesicles are considered, which points to differences in membrane transport rates (Torres, 1996; Morris et al., 2003). Apart from greater membrane fluidity of female hepatocytes, the higher hepatocellularity in this gender may also justify such differences. Likewise, male rats and men have higher serum bilirubin levels (Muraca et al., 1983; Zucker et al., 2004). This has been postulated to be due to hormonal influences because orchietomized rats have levels

similar to females, and in humans the gender disparity in bilirubin only occurs after the age of 10 years (Zucker et al., 2004).

Yet, the higher hepatocellularity in female rats (and hypothetically in women) raises concerns over the effects of ovariectomy (or menopause) in liver structure. This is still controversial in rats: studies comparing the numerical density of HEP in ovariectomized rats reached opposite conclusions (Trujillo et al., 2001; Dursun et al., 2010; Oral et al., 2012). In the line of the stereological data (Marcos, 2013), we would suggest a reduction of hepatocellularity post-ovariectomy (and post-menopause), with consequential remodelling, which would justify an increase in hepatic transaminases post-ovariectomy seen in rats (Oral et al., 2012). In women, such an increase is extremely hard to notice, because it is difficult to separate the influences of aging and menopause in the liver.

There are other “menopause-like” scenarios of major clinical relevance in the liver, like the gender-mismatch liver transplantation (i.e., when a woman’s liver is transplanted to a man). Twenty years ago, Marino et al. (1995) highlighted a poorer prognosis of this transplant, either comparing it with male to female transplant or with gender-matched liver transplantations. The reasons behind gender-mismatch have been extensively debated (Burra et al., 2013). Some ascribed it to confounding factors (Rustgi et al., 2002), whilst others suggested that it could be due to poorer quality of female organs (female donors tended to be older, shorter and died more frequently of stroke) (Lai et al., 2012). However, the most recent studies, with a large series of cadaveric donors (Croome et al., 2014), as well as studies with living donor organs (in which the argument of poorer quality of organs does not stand) stressed the importance of gender-mismatch (Yoshizumi et al., 2012). The influence of estrogens was further stressed by the fact that gender mismatch does not occur before the onset of puberty (Pillay et al., 1990). The reasons behind the gender mismatch are still unknown. Experimental studies have shown that female livers develop more lactic acidosis during warm ischemia, compared with males (Wittnich et al., 2004) and this was estrogen

dependent. The insight that the female liver has higher hepatocellularity would also justify the reported increased lactate production (Wittnich et al., 2004).

Consequences of our hypothesis

Even if it is often assumed that no organ differences exist between male and female liver, recent research (including ours) suggests otherwise. We hypothesize that the structural gender differences observed in rat (Figure 1, Table1) may also take place in humans.

It may be said that the roots of our hypothesis date back to the Greeks and to the Promethean myth. In this fascinating allegory, an eagle daily devoured the liver of Prometheus, which regenerated overnight. More than eighty years ago the first report on experimental induction of liver regeneration confirmed the forecasts of ancient mythographers (Higgins and Anderson, 1931). Our hypothesis globally suggests that an alternative version of the Promethean myth, namely, a female Prometheus would be more accurate. Before the continuous insult by the eagle, a female Prometheus' liver would have less collagen (and lower amounts of fibrotic tissue would be deposited during the chronic injury). With an increased number of HEP (with more diploid particles) her liver would regenerate faster and finally, with more KC it would respond better to the recurring infection due to the eagle's beak.

Returning to our time, the consequences of the gender dimorphism in liver structure and cell composition encompass liver fibrosis, alcoholic injury and post-hepatectomy regeneration, thus sustaining the concept of gender specific hepatology. Another consequence of our hypothesis resides in liver transplantation, since structural dimorphism may help explain gender-mismatch liver transplantation. It may be hypothesized that when deprived with of estrogenic milieu (inherent to transplantation in a male recipient), the highly hepatocellular female liver may start remodeling and the HEP apoptosis may trigger an increased production of pro-inflammatory interleukins

(by the more numerous KC population). Eventually, this may sentence the female organ to a poorer outcome in the male recipient.

In conclusion, liver gender dimorphism extends from genes and enzymatic activities up to the morphological level, at least in the rat. The functional significance of differences in HEP, KC and in collagen disclosed herein are still poorly understood. However, these differences should be considered in the complex puzzle of gender dimorphism. In order to see the whole picture of gender hepatology, it would be relevant to discover whether the gender dimorphic pattern of rat liver also takes place in the human organ.

References

- Bian H., Hakkarainen A., Zhou Y., Lundbom N., Olkkonen V.M. and Yki-Järvinen H. (2015). Impact of non-alcoholic fatty liver disease on liver volume in humans. *Hepatol. Res.* 45, 210-219.
- Biondo-Simões M. de L., Erdmann T.R., Ioshii S.O., Matias J.E., Calixto H.L. and Schebelski D.J. (2009). The influence of estrogen on liver regeneration: an experimental study in rats. *Acta Cir. Bras.* 24, 3-6.
- Burra P., De Martin E., Gitto S. and Villa E. (2013). Influence of age and gender before and after liver transplantation. *Liver Transpl.* 19, 122-134.
- Chiu E.J., Lin H.L., Chi C.W., Liu T.Y. and Lui W.Y. (2002). Estrogen therapy for hepatectomy patients with poor liver function? *Med. Hypotheses* 58, 516-518.
- Choudhry M.A., Schwacha M.G., Hubbard W.J., Kerby J.D., Rue L.W. and Bland K.I. (2005). Gender differences in acute response to trauma-hemorrhage. *Shock* 24, 101-106.
- Choukèr A., Martignoni A., Dugas M., Eisenmenger W., Schauer R., Kaufmann I., Schelling G., Löhe F., Jauch K.-W., Peter K. and Thiel M. (2004). Estimation of liver size for liver transplantation: the impact of age and gender. *Liver Transpl.* 10, 678-685.
- Cohen B., Choi Y.J., Hyman S., Furuya E.Y., Neidell M. and Larson E. (2013). Gender differences in risk of bloodstream and surgical site infections. *J. Gen. Intern. Med.* 28, 1318-1325.
- Colantoni A., Paglia N., De Maria N., Emanuele M.A., Emanuele N.V., Idilman R., Harig J. and Van Thiel D.H. (2000). Influence of sex hormonal status on alcohol-induced oxidative injury in male and female rat liver. *Alcohol Clin. Exp. Res.* 24, 1467-1473.
- Colombo S., Belloli L., Zaccanelli M., Badia E., Jamoletti C., Buonocore M. and Poggio P.D. (2011). Normal liver stiffness and its determinants in healthy blood donors. *Dig. Liv. Dis.* 43, 231-236.
- Corpechot C., Nagar A. and Poupon R. (2006). Gender and the liver: is the liver stiffness weaker in the weaker sex? *Hepatology* 44, 513-514.

Croome K.P., Segal D., Hernandez-Alejandro R., Adams P.C., Thomson A. and Chandok N. (2014). Female donor to male recipient gender discordance results in inferior graft survival: a prospective study of 1,042 liver transplants. *J. Hepatobiliary Pancreat. Sci.* 21, 269-274.

Da Costa V.M.C., Moreira D.G. and Rosenthal D. (2001). Thyroid function and aging: gender related differences. *J. Endocrinol.* 171, 193-198.

Di Martino V., Lebray P., Myers R.P., Pannier E., Paradis V., Charlotte F., Moussalli J., Thabut D., Buffet C. and Poynard T. (2004). Progression of liver fibrosis in women infected with hepatitis C: long-term benefit of estrogen exposure. *Hepatology* 40, 1426-1433.

Durazzo M., Belci P., Collo A., Prandi V., Pistone E., Martorana M., Gambino R. and Bo S. (2014). Gender specific medicine in liver diseases: a point of view. *World J. Gastroenterol.* 20, 2127-2135.

Dursun H., Albayrak F., Uyanik A., Keleş N.O., Beyzagül P., Bayram E., Halici Z., Altunkaynak Z.B., Süleyman H., Okçu N. and Ünal B. (2010). Effects of hypertension and ovariectomy on rat hepatocytes. Are amlodipine and lacidipine protective? A stereological and histological study. *Turk. J. Gastroenterol.* 21, 387-395.

Eagon P.K. (2010). Alcoholic liver injury: influence of gender and hormones. *World J. Gastroenterol.* 16, 1377-1384.

Facciuto M., Contreras-Saldivar A., Singh M.K., Rocca J.P., Taouli B., Oyfe I., LaPointe Rudow D., Gondolesi G.E., Schiano T.D., Kim-Schluger L., Schwartz M.E., Miller C.M. and Florman S. (2013). Right hepatectomy for living donation: role of remnant liver volume in predicting hepatic dysfunction and complications. *Surgery* 153, 619-626.

Fisher B., Gunduz N., Saffer E.A. and Zheng S. (1984). Relation of estrogen and its receptor to rat liver growth and regeneration. *Cancer Res.* 44, 2410-2415.

FrancaVilla A., Eagon P.K., DiLeo A., Polimeno L., Panella C., Aquilino A.M., Ingrosso M., Van Thiel D.H. and Starzl T.E. (1986). Sex hormone-related functions in regenerating male rat liver. *Gastroenterology* 91, 1263-1270.

Gandillet A., Alexandre E., Holl V., Royer C., Bischoff P., Cinqualbre J., Wolf P., Jaeck D. and Richert L. (2003). Hepatocyte ploidy in the normal rat. *Comp. Biochem. Physiol. A Mol. Integr. Physiol.* 134, 665-673.

Guy J. and Peters M.G. (2013). Liver disease in women: the influence of gender on epidemiology, natural history, and patient outcomes. *Gastroenterol. Hepatol.* 9, 633-639.

Higgins J.M. and Anderson R.M. (1931). Experimental pathology of the liver. I. Restoration of the liver of the white rat following partial surgical removal. *Arch. Pathol.* 12, 186-202.

Huang H., He J., Yuan Y., Aoyagi E., Takenaka H., Itagaki T., Sannomiya K., Tamaki K., Harada N., Shono M., Shimizu I. and Takayama T. (2008). Opposing effects of estradiol and progesterone on the oxidative stress-induced production of chemokine and proinflammatory cytokines in murine peritoneal macrophages. *J. Med. Invest.* 55, 133-141.

Kam I., Lynch S., Svanas G., Todo S., Polimeno L., Francavilla A., Penkrot R.J., Takaya S., Ericzon B.G., Starzl T.E. and Van Thiel D.H. (1987). Evidence that host size determines liver size: studies in dogs receiving orthotopic liver transplants. *Hepatology* 7, 362-366.

Kitagawa T., Yokoyama Y., Kokuryo T., Kawai T., Watanabe K., Kawai K. and Nagino M. (2009). Estrogen promotes hepatic regeneration via activating serotonin signal. *Schock* 31, 615-620.

Kwekel J.C., Desai V.G., Moland C.L., Branham W.S. and Fuscoe J.C. (2010). Age and sex dependent changes in the liver gene expression during the life cycle of the rat. *BMC Genomics* 11, 675.

Imamura H., Shimada R., Kubota M., Matsuyama Y., Nakayama A., Miyagawa S.-I., Makuuchi M. and Kawasaki S. (1999). Preoperative portal vein embolization: an audit of 84 patients. *Hepatology* 29, 1099-1105.

Lai J.C., Feng S. and Roberts J.P. (2012). An examination of liver offers to candidates on the liver transplant wait-list. *Gastroenterology* 143, 1261-1265.

Li Z., Tuteja G., Schug J. and Kaestner K.H. (2012). Foxa1 and Foxa2 are essential for sexual dimorphism in liver cancer. *Cell* 148, 72-83.

Marcos R. (2013). Age and gender influences on the rat liver model: quantitative morphological studies of hepatic stellate cells, hepatocytes and Kupffer cells and of related functional parameters. PhD Thesis. Institute of Biomedical Sciences Abel Salazar, University of Porto.

Marcos R. and Correia-Gomes C. (2014). The innate immune system of the liver: May it explain the stronger viral clearance in female sex? *Hepatology* 60, 1800-1801.

Marcos R. and Correia-Gomes C. (2015). Liver and gender: are there differences in fibrous tissue before the onset of fibrosis? *Hepatology* 61, 1093-1094.

Marino I.R., Doyle H.R., Aldrighetti L., Doria C., McMichael J., Gayowski T., Fung J.J., Tzakis A.G. and Starzl T.E. (1995). Effect of donor age and sex on the outcome of liver transplantation. *Hepatology* 22, 1754-1762.

McCuskey R.S., McCuskey P.A., Urbaschek R. and Urbaschek B. (1984). Species differences in Kupffer cells and endotoxin sensitivity. *Infect. Immun.* 45, 278-280.

Morris M.E., Lee H.-J. and Predko L.M. (2003). Gender differences in the membrane transport of endogenous and exogenous compounds. *Pharmacol. Rev.* 55, 229-240.

Mugford C.A. and Kedderis G.L. (1998). Sex-dependent metabolism of xenobiotics. *Drug Metab. Rev.* 30, 441-498.

Muraca M., De Groote J. and Fevery J. (1983). Sex differences of hepatic conjugation of bilirubin determine its maximal biliary excretion in non-anaesthetized male and female rats. *Clin. Sci.* 64, 85-90.

Nicol T and Veron-Roberts B. (1965). The influence of the estrus cycle, pregnancy and ovariectomy on RES Activity. *J. Reticuloendothel. Soc.* 60, 15-29.

Offner P.J., Moore E.E. and Biffi W.L. (1999). Male gender is a risk factor for major interactions after surgery. *Arch. Surg.* 134, 935-938.

Oral A., Unal D., Halici Z., Cadirci E., Sengul O., Gundogdu C., Unal B. and Atamanalp S.S. (2012). Bilateral ovariectomy in young rats: what happens in their livers during cecal ligation and puncture induced sepsis? *J. Pediatr. Adolesc. Gynecol.* 25, 371-379.

Pfeilschifter J., Köditz R., Pfohl M. and Schatz H. (2002). Changes in proinflammatory cytokine activity after menopause. *Endocrine Rev.* 23, 90-119.

Pillay P., Van Thiel D.H., Gavaler J.S. and Starzl T.E. (1990). Donor gender does not affect liver transplantation outcome in children. *Dig. Dis. Sci.* 35, 686-689.

Porter L.E., Elm E.S., Van Thiel D.H. and Eagon P.K. (1987). Hepatic estrogen receptor in human liver disease. *Gastroenterology* 92, 735-745.

Roulout D., Czernichow S., Clésiau H., Costes J.-L., Vergnaud A.-C. and Beaugard M. (2008). Liver stiffness values in apparently healthy subjects: influence of gender and metabolic syndrome. *J. Hepatol.* 48, 606-613.

Ruhl C.E. and Everhart J.E. (2002). Upper limits of normal for alanine aminotransferase activity in the United States population. *Hepatology* 55, 447-454.

Rustgi V.K., Marino G., Halpern M.T., Johnson L.B., Umana W.O. and Tolleris C. (2002). Role of gender and race mismatch and graft failure in patients undergoing liver transplantation. *Liver Transpl.* 8, 514-518.

Sereemasapun A., Takeuchi K., Sato Y., Iwamoto S., Inakagi T., Ookawara S., Hakamata Y., Murakami T. and Kobayashi E. (2005). Testosterone-dependent transgene expression in the liver of the CAG-lacZ transgenic rat. *Gene Expression* 12, 305-313.

Scotland R.S., Stables M.J., Madalli S., Watson P. and Gilroy D.W. (2011). Sex differences in resident immune cell phenotype underlie more efficient acute inflammatory responses in female mice. *Blood* 118, 5918-5927.

Schleicher J., Tokarski C., Marbach E., Matz-Soja M., Zellmer S., Gebhardt R. and Schuster S. (2015). Zonation of hepatic fatty acid metabolism — the diversity of its regulation and the benefit of modelling. *Biochim. Biophys. Acta* 1851, 641-656.

Schröder J., Kahlke V., Staubach K.-H., Zabel P. and Stüber F. (1998). Gender differences in human sepsis. *Arch. Surg.* 133, 1200-1205.

Shan Y.S., Hsieh Y.H., Sy E.D., Chiu N.T. and Lin P.W. (2005). The influence of spleen size on liver regeneration after major hepatectomy in normal and early cirrhotic liver. *Liver Int.* 25, 96-100.

Shimizu I., Mizobuchi Y., Yasuda M., Shiba M., Ma Y.-R., Horie T., Liu F. and Ito S. (1999). Inhibitory effect of estradiol on activation of rat hepatic stellate cells in vivo and in vitro. *Gut* 44, 127-136.

Shimizu I., Kohno N., Tamaki K., Shono M., Huang H.W., He J.H. and Yao D.F. (2007). Female hepatology: favorable role of estrogen in chronic liver disease with hepatitis B virus infection. *World J. Gastroenterol.* 13, 4295-4305.

Sirma H., Williams G.M. and Gebhardt R. (1996). Strain- and sex-specific variations in hepatic glutamine synthetase activity and distribution in rats and mice. *Liver* 16, 166-173.

Tacke F. and Zimmermann H.W. (2014). Macrophage heterogeneity in liver injury and fibrosis. *J. Hepatol.* 60, 1090-1096.

Teutsch H.F. (1984). Sex-specific regionality of liver metabolism during starvation; with special reference to the heterogeneity of the lobular periphery. *Histochemistry* 81, 87-92.

Thurman R.G. (1998). Alcoholic liver injury involves activation of Kupffer cells by endotoxin. *Am. J. Physiol.* 275, G605-611.

Torres A.M. (1996). Gender-differential liver plasma membrane affinities in hepatic tetrabromosulfonephthalein (TBS) uptake. *Biochem. Pharmacol.* 51, 1117-1122.

Trujillo E., Vásquez B. and Del Sol M. (2001). Stereologic characteristics of the liver of rats (*Rattus norvegicus*) submitted to ovariectomy-induced menopause. *Int. J. Morphol.* 29, 1470-1478.

Tsukamoto I. and Kojo S. (1990). The sex difference in the regulation of liver regeneration after partial hepatectomy in the rat. *Biochim. Biophys. Acta* 1033, 287-290.

Udy G.B., Towers R.P., Snell R.G., Wilkins R.J., Park S.H., Ram P.A., Waxman D.J. and Davey H.W. (1997). Requirement of STAT5b for sexual dimorphism of body growth rates and liver gene expression. *Proc. Natl. Acad. Sci. U.S.A.* 94, 7239-7244.

Vickers A.E. and Lucier G.W. (1996). Estrogen receptor levels and occupancy in hepatic sinusoidal endothelial and Kupffer cells are enhanced by initiation with diethylnitrosamine and promotion with 17 alpha-ethinylestradiol in rats. *Carcinogenesis* 17, 1235-1242.

Villa E., Vukotic R., Cammà C., Petta S., Di Leo A., Gitto S., Turola E., Karampatou A., Losi L., Bernabucci V., Cenci A., Tagliavini S., Baraldi E., De Maria N., Gelmini R., Bertolini E., Rendina M. and Francavilla A. (2012). Reproductive status is associated with the severity of fibrosis in women with hepatitis C. *PloS One* 7, e44624.

Waxman D.J. and Holloway M.G. (2009). Sex differences in the expression of hepatic drug metabolizing enzymes. *Mol. Pharmacol.* 76, 215-228.

Witnich C., Belanger M.P., Askin N., Boscarino C. and Wallen W.J. (2004). Lower liver transplant success in females: gender differences in metabolic response to global ischemia. *Transplant Proc.* 36, 1485-1488.

Xu J.W., Gong J., Chang X.M., Luo J.Y., Dong L., Hao Z.M., Jia A. and Xu G.P. (2002). Estrogen reduces CCl₄-induced liver fibrosis in rats. *World J. Gastroenterol.* 8, 883-887.

Yang X., Schadt E.E., Wang S., Wang H., Arnold A.P., Ingram-Drake L., Drake T.A. and Lusis A.J. (2006). Tissue-specific expression and regulation of sexually dimorphic genes in mice. *Genome Res.* 16, 995-1004.

Yang J.D., Abdelmalek M.F., Pang H., Guy C.D., Smith A.D., Diehl A.M. and Suzuki A. (2014). Gender and menopause impact severity of fibrosis among patients with nonalcoholic steatohepatitis. *Hepatology* 59, 1406-1414.

Yasuda M., Shimizu I., Shiba M. and Ito S. (1999). Suppressive effects of estradiol on dimethylnitrosamine-induced fibrosis of the liver in rats. *Hepatology* 29, 719-727.

Yokoyama Y., Nimura Y., Nagino M., Bland K.I. and Chaudry I.H. (2005). Current understanding of gender dimorphism in hepatic pathophysiology. *J. Surg. Res.* 128, 147-156.

Yokoyama Y., Nagino M. and Nimura Y. (2007). Which gender is better positioned in the process of liver surgery? Male or female? *Surgery Today* 37, 823-830.

Yokoyama Y., Nagino M., Oda K., Nishio H., Ebata T., Abe T., Igami T. and Nimura Y. (2008). Sex dimorphism in the outcome of preoperative right portal vein embolization. *Arch. Surg.* 143, 254-259.

Yoshizumi T., Shirabe K., Taketomi A., Uchiyama H., Harada N., Ijichi H., Yoshimatsu M., Ikegami T., Soejima Y. and Maehara Y. (2012). Risk factors that increase mortality after living donor liver transplantation. *Transplantation* 93, 93-98.

Zarski J.P., Marcellin P., Leroy V., Trepo C., Samuel D., Ganne-Carrie N., Barange K., Canva V., Doffoel M. and Cales P. (2006). Characteristics of patients with chronic hepatitis B in France: predominant frequency of HBe antigen negative cases. *J. Hepatol.* 45, 355-360.

Zhang Y., Klein K., Sugathan A., Nassery N., Dombkowski A., Zanger UM. and Waxman D.J. (2011). Transcriptional profiling of human liver identifies sex-biased genes associated with polygenic dyslipidemia and coronary artery disease. *PLoS One* 6, e23506.

Zucker S.D., Horn P.S. and Sherman K.E. (2004). Serum Bilirubin levels in the U.S. population: effect and inverse correlation with colorectal gender cancer. *Hepatology* 40, 827-835.

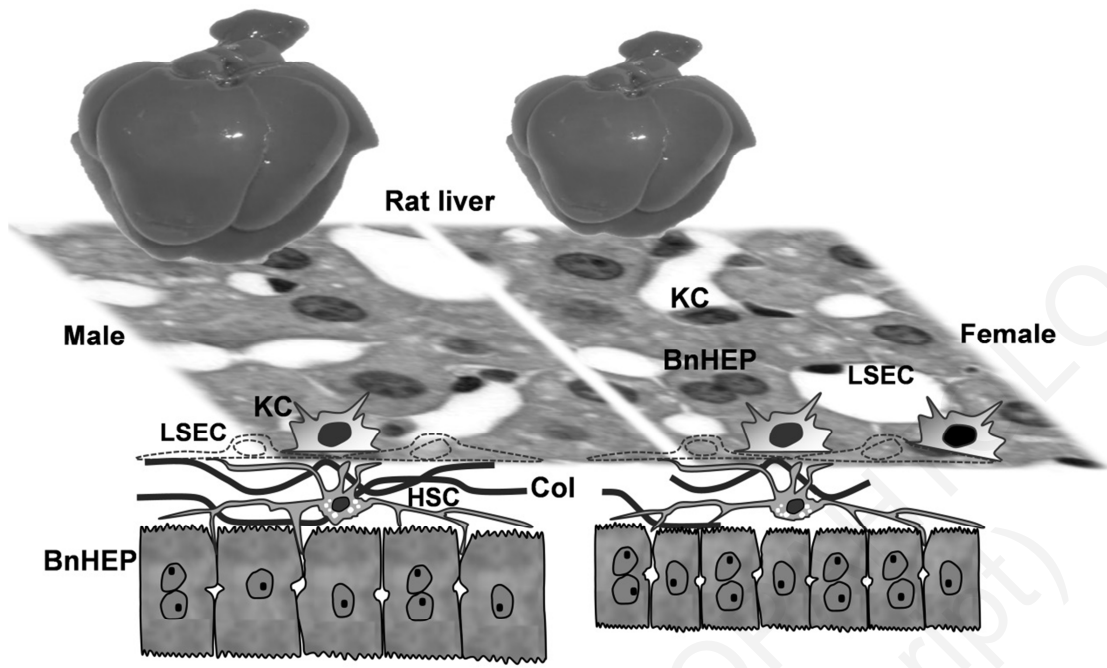
Table 1 – Structural parameters influenced by gender

Parameter (unit)	Male	Female	<i>P</i> -value*
Liver weight (g)	15.15 ± 1.62	10.14 ± 1.24	<0.0001
$V_V(\text{collagen, liver})$ (%)	2.53 ± 0.82	1.89 ± 0.38	0.018
$N_V(\text{KC, liver})$ ($\times 10^3$ KC per mm^3)	23.10 ± 3.25	27.69 ± 4.73	0.003
$N_V(\text{HEP, liver})$ ($\times 10^3$ HEP per mm^3)	163.59 ± 23.27	204.79 ± 37.71	0.001
BnHEP (% to HEP)	24.10 ± 4.29	32.95 ± 5.99	<0.0001
MnHEP volume (μm^3)	5206 ± 599	4710 ± 515	0.029
BnHEP volume (μm^3)	7865 ± 1507	6861 ± 1189	NS

Values expressed as mean ± standard deviation. (*) *P*-values result from Student's *T* test, except for $V_V(\text{collagen, liver})$ in which Mann-Whitney was used. NS: non-significant; KC: Kupffer cells; HEP: Hepatocytes; MnHEP: Mononuclear hepatocytes; BnHEP: Binuclear hepatocytes.

Figure 1 – Overview of the structural parameters in rat liver that are influenced by gender. Male liver is larger, with more collagen (Col) deposition and mononuclear hepatocytes (MnHEP) are also larger. However, per unit of volume, it has 20% less Kupffer cells (KC) and 25% less Hepatocytes (HEP) and less binuclear hepatocytes (BnHEP). HSC: hepatic stellate cell; LSEC: liver sinusoidal endothelial cell.

HISTOLOGY AND HISTOPATHOLOGY
(non-edited manuscript)



HISTOLOGY AND HISTOPATHOLOGY
(non-edited manuscript)